The Cortex (CN II)

Lab 5

February 2, 2026 - Dr. Stiver (mikaela.stiver@ubc.ca)

Objectives:

1. Describe and localize the lobes of the cerebral cortex and their major components.
2. Compare and contrast the functional components of the right and left hemispheres and localize the functional areas.
3. Analyze the deficit that would result from cortical lesions to the different functional areas and differentiate between right and left hemisphere lesions.
4. Explain the classical cortical representation of language and its clinical significance.
5. Describe the location of the major subcortical fiber bundles.
6. Describe the tracts running through the internal capsule, their location within the internal capsule, and the blood supply to the internal capsule.
7. Describe the function of the thalamus as the gatekeeper to the cortex. Describe which systems relay through the thalamus.
8. Integrate the components of the visual pathway from the retina to the cortex with the clinical symptoms of visual deficits.
9. Review the visual system and localize the relevant tracts and structures.
10. Describe the blood supply to the forebrain.

Resources

Here are the e-tutorials, videos and web resources for this lab – click the green buttons to access them.

Web Syllabus & Links

Videos:

Subcortical Fiber Tracts (Video)

Visual Pathway (Video)

Modules:

Cortex (Module)

Language (Module)

Cerebral Arterial Circle (Module)

Visual System (Module)

3D Models:

Half Brain (3D)

Subcortical Fibers (3D)

Visual Tracts (3D)

Whole Brain 1 (3D)

Commissural Fibers (3D)

Optic Radiations (3D)

Whole Brain 2 (3D)

Sup. Long. Fasciculus (3D)

Cerebral Arterial Circle (3D)

*This icon located throughout the lab manual indicates **checklist items**!*

** NOTE: Interactive PDFs are best viewed on desktop/laptop computers – functionality is not reliable on mobile devices **

February 2, 2026 - Dr. Stiver (*mikaela.stiver@ubc.ca*)

Identify the following functional areas on the brain specimens and describe their location. What are the landmarks? Which hemisphere are they in?

Cortex (Module)

Colour and label this diagram to show the following functional areas:

- ◯ Primary motor cortex
- ◯ Supplementary motor areas
- ◯ Primary sensory cortex
- ◯ Supplementary sensory areas

Classical language areas of the cortex:

- ◯ Broca
- ◯ Wernicke

February 2, 2026 - Dr. Stiver (mikaela.stiver@ubc.ca)

Cerebral Lobes & Components

Identify the following structures of the brain:

Major Sulci & Gyri

- ◯ Longitudinal fissure
  - separates the 2 cerebral hemispheres
- ◯ Central sulcus
  - separates frontal and parietal lobes
- ◯ Lateral fissure
  - separates frontal and parietal lobes from temporal lobe
- ◯ Parieto-occipital sulcus
  - on medial surface, separates occipital lobe from parietal / temporal lobes
- ◯ Calcarine fissure
  - on medial surface in occipital lobe
- ◯ Precentral gyrus
  - anterior to central sulcus
  - primary motor area
- ◯ Postcentral gyrus
  - posterior to central sulcus
  - primary somatosensory area

Lobes

- ◯ Frontal
- ◯ Parietal
- ◯ Occipital
- ◯ Temporal
- ◯ Limbic

Hide Labels

Superior/Dorsal Cortex

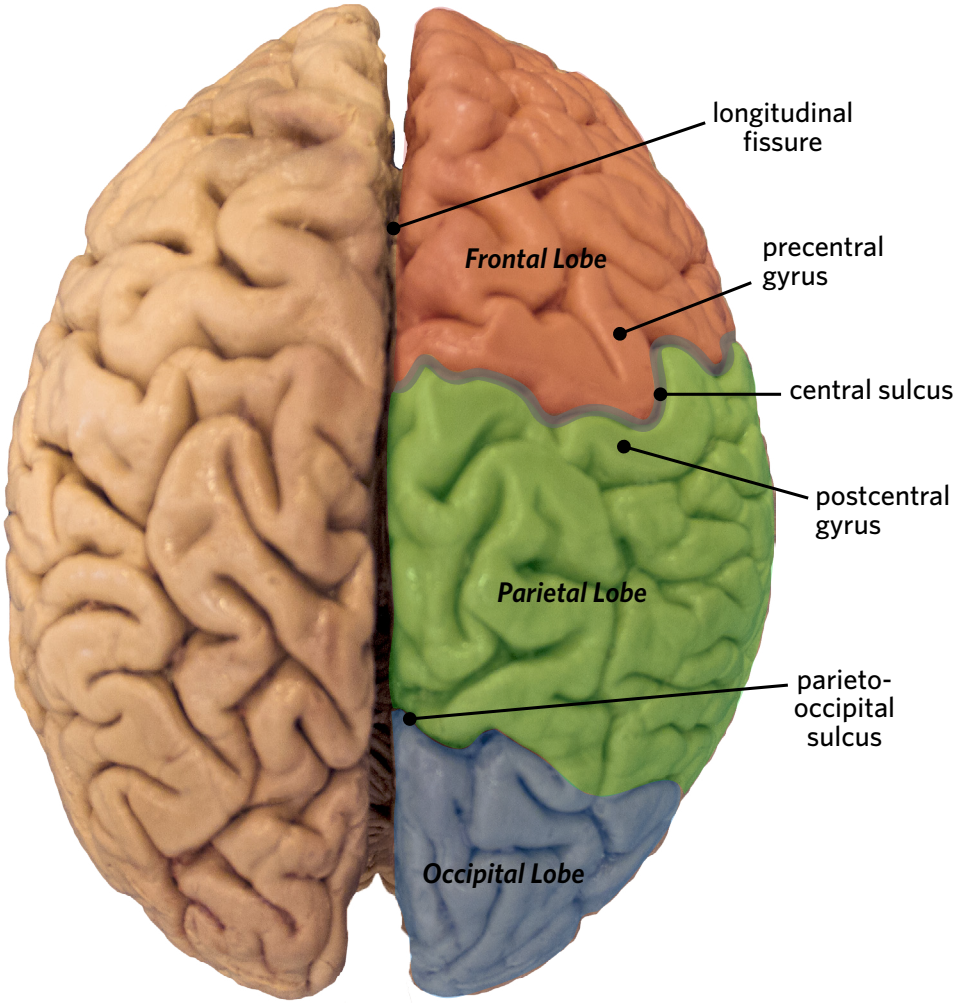

February 2, 2026 - Dr. Stiver (*mikaela.stiver@ubc.ca*)

Hide Labels

Lateral Cortex

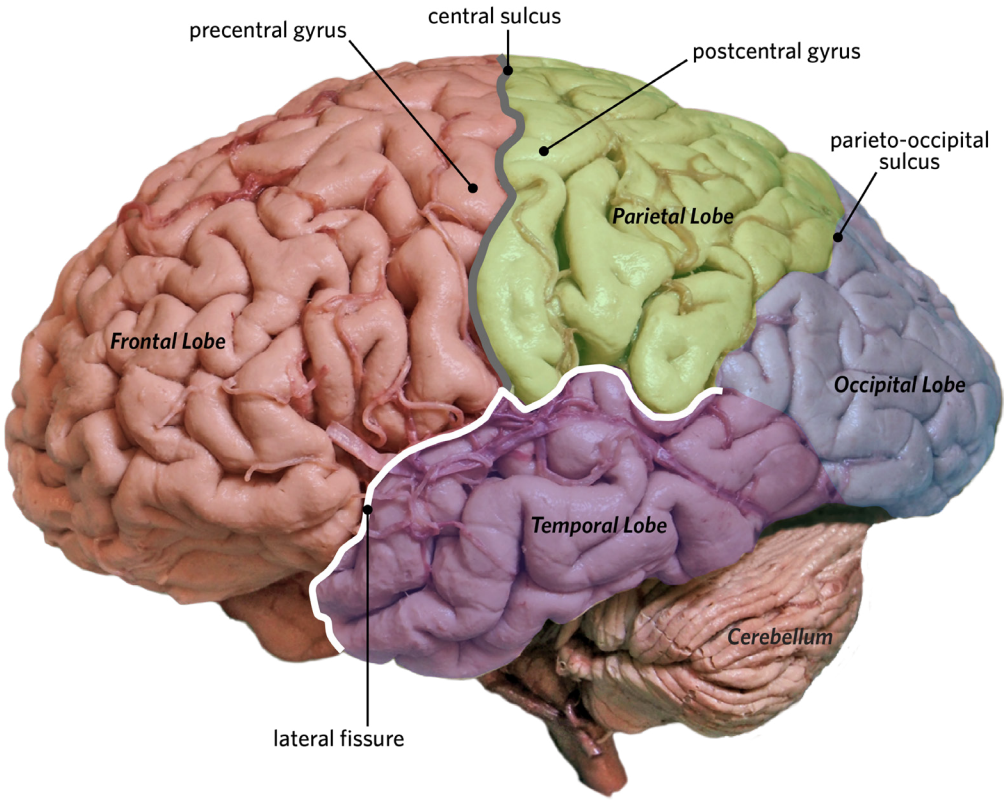

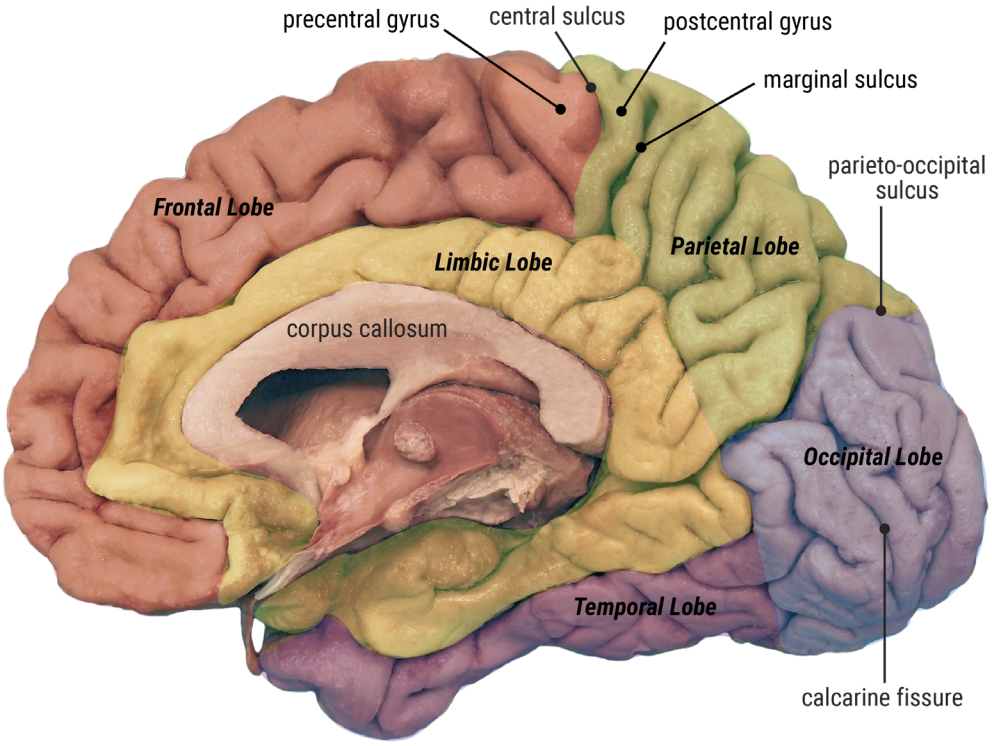

Hide Labels

Medial Cortex

February 2, 2026 - Dr. Stiver (mikaela.stiver@ubc.ca)

Whole Brain

- ◯ **Primary areas:** motor, sensory, visual, olfactory, auditory
- ◯ **Association areas:** motor, sensory, visual, olfactory, auditory
- ◯ **Language areas:** Broca, Wernicke
- ◯ **Heteromodal association areas:** frontal, parietal, temporal

Half Brain

- ◯ Corpus callosum: genu, body & splenium
- ◯ Anterior commissure
- ◯ Posterior commissure

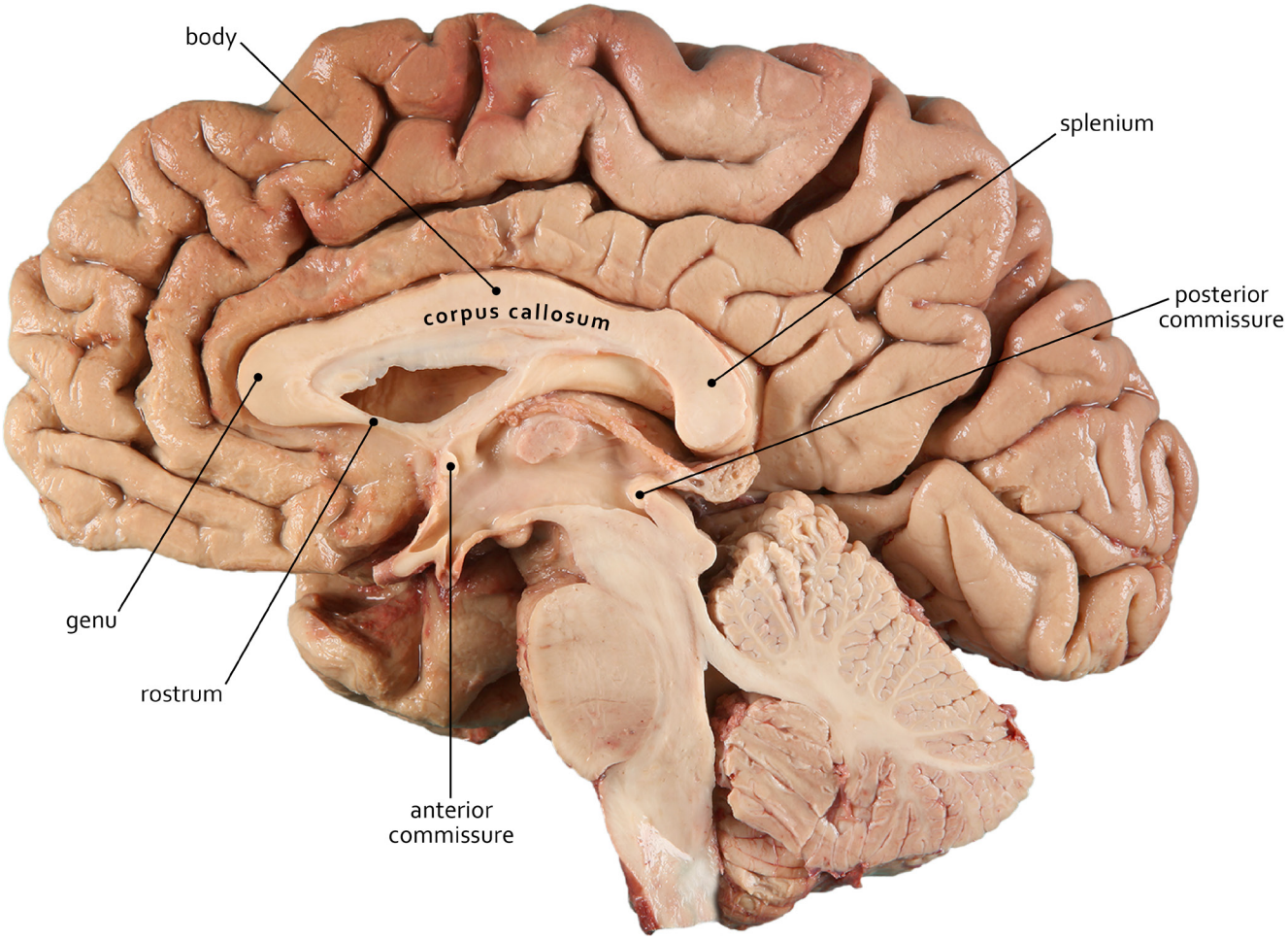

Commissural Fibers in Medial Brain

Hide Labels

February 2, 2026 - Dr. Stiver (*mikaela.stiver@ubc.ca*)

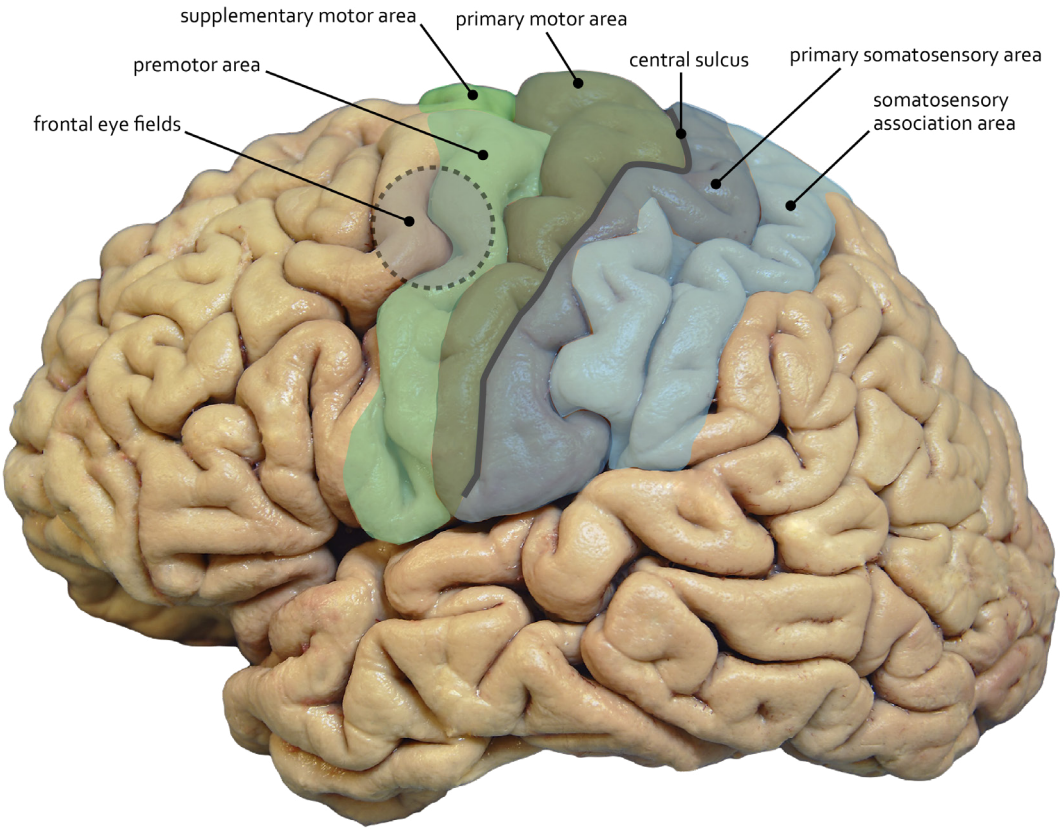

Motor and Sensory Areas on Lateral Brain

Hide Labels

Insula and Auditory Areas

Hide Labels

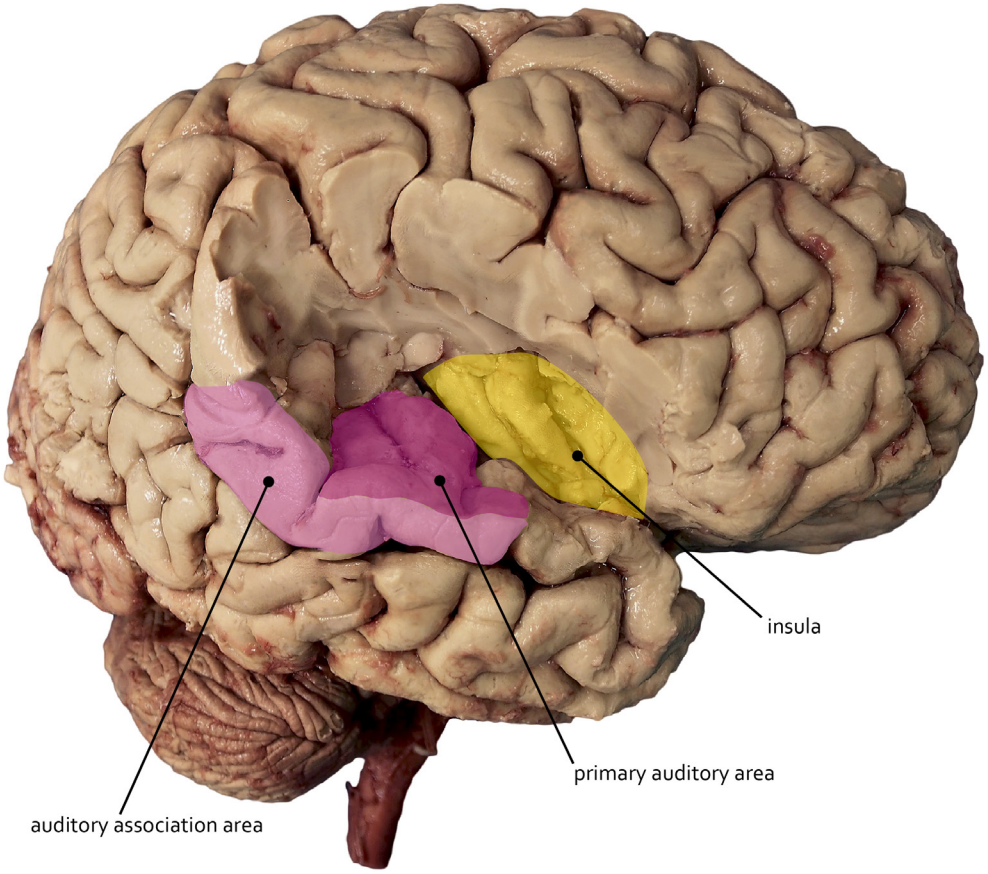

February 2, 2026 - Dr. Stiver (mikaela.stiver@ubc.ca)

Language

Language (Module)

What are the clinical symptoms of Broca's aphasia?

What are the clinical symptoms of Wernicke's aphasia?

What are the clinical symptoms of conduction aphasia?

February 2, 2026 - Dr. Stiver (mikaela.stiver@ubc.ca)

Case #1

Ms. Hammadi, a 42 year old right-handed woman (she/her) presents with right upper and lower extremity weakness. She has word finding difficulties, normal comprehension, impaired repetition and non-fluent speech.

List the symptoms and the possible structures involved.

What is the most likely site of the lesion? Why?

Which vascular territory is involved?

Illustration: Milo Applejohn

February 2, 2026 - Dr. Stiver (mikaela.stiver@ubc.ca)

Fiber Tracts

- ◯ Superior longitudinal fasciculus
- ◯ Arcuate fibers
- ◯ Uncinate fasciculus
- ◯ Inferior occipitofrontal fasciculus
- ◯ Cingulum
- ◯ Corona radiata and internal capsule

DTI Tracts (3D)

Association Fibers
are confined to the same hemisphere. Short association fibers connect cortical areas in adjacent gyri; long association fibers pass between cortical areas that are further removed from each other.

Association Fibers in Lateral Brain Dissection

Hide Labels

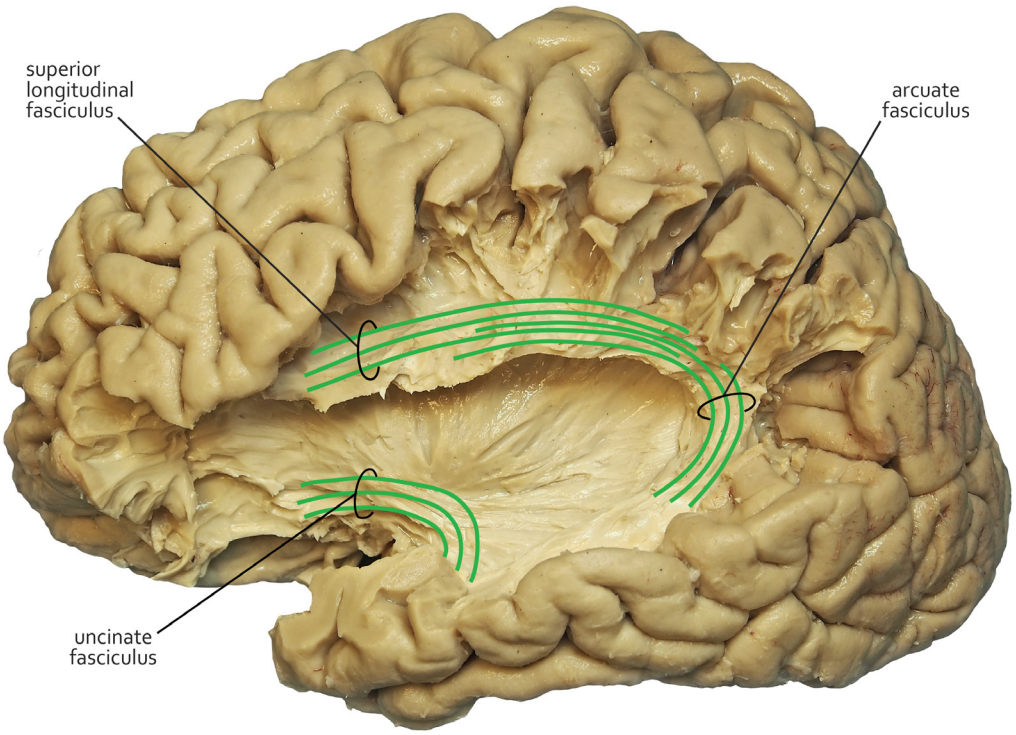

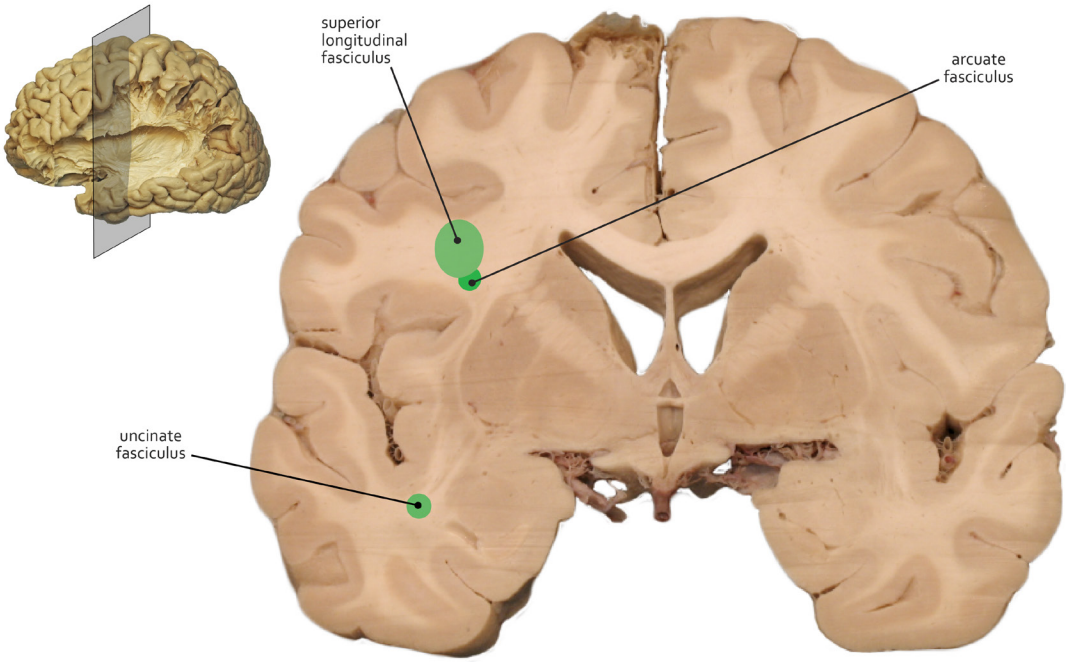

Association Fibers in Coronal Section

Hide Labels

The Cortex (CN II)

February 2, 2026 - Dr. Stiver (mikaela.stiver@ubc.ca)

Draw in the following structures on the diagrams and identify on brain specimens:

Horizontal Section:

- ◯ **Corpus callosum:** forceps major, forceps minor
- ◯ Anterior and posterior commissures
- ◯ **Internal capsule:** anterior limb, posterior limb, genu

Coronal Section:

- ◯ Corpus callosum
- ◯ Anterior commissure
- ◯ **Internal capsule:** anterior limb, posterior limb

Check out the interactive atlas with cross-sections:

Horizontal Sections (Web)

Coronal Sections (Web)

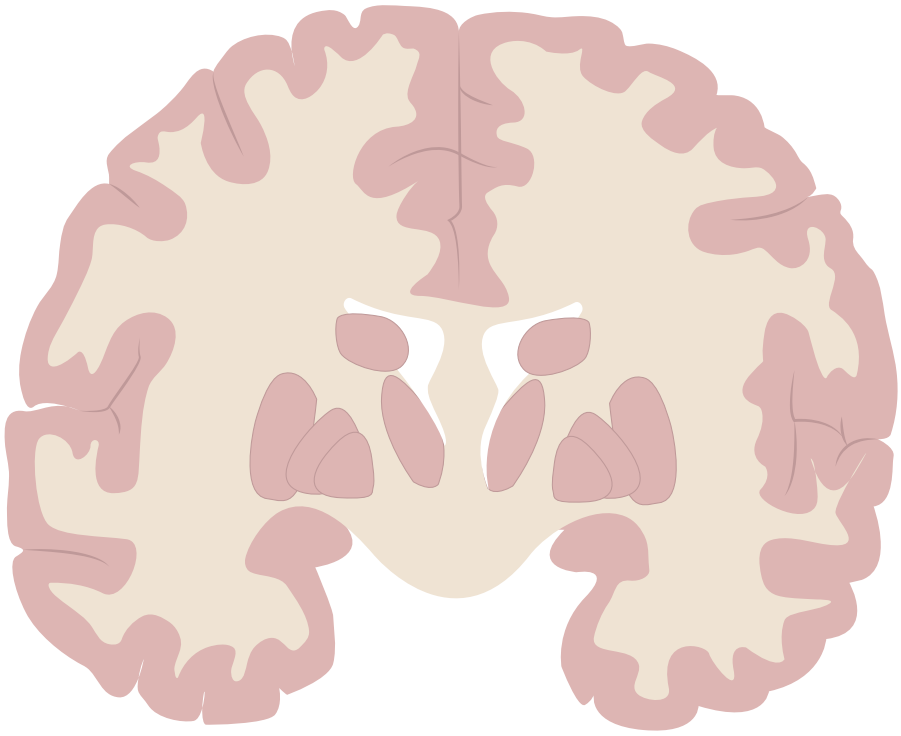

February 2, 2026 - Dr. Stiver (mikaela.stiver@ubc.ca)

Thalamus

The thalamus is often considered to be the functional "gatekeeper" to the cerebral cortex. It consists of 2 egg-shaped masses of gray matter bordering the third ventricle, and is divided into many nuclei with motor, sensory and association functions.

Schematic Representation of the THALAMUS
(viewed from superior - horizontal)

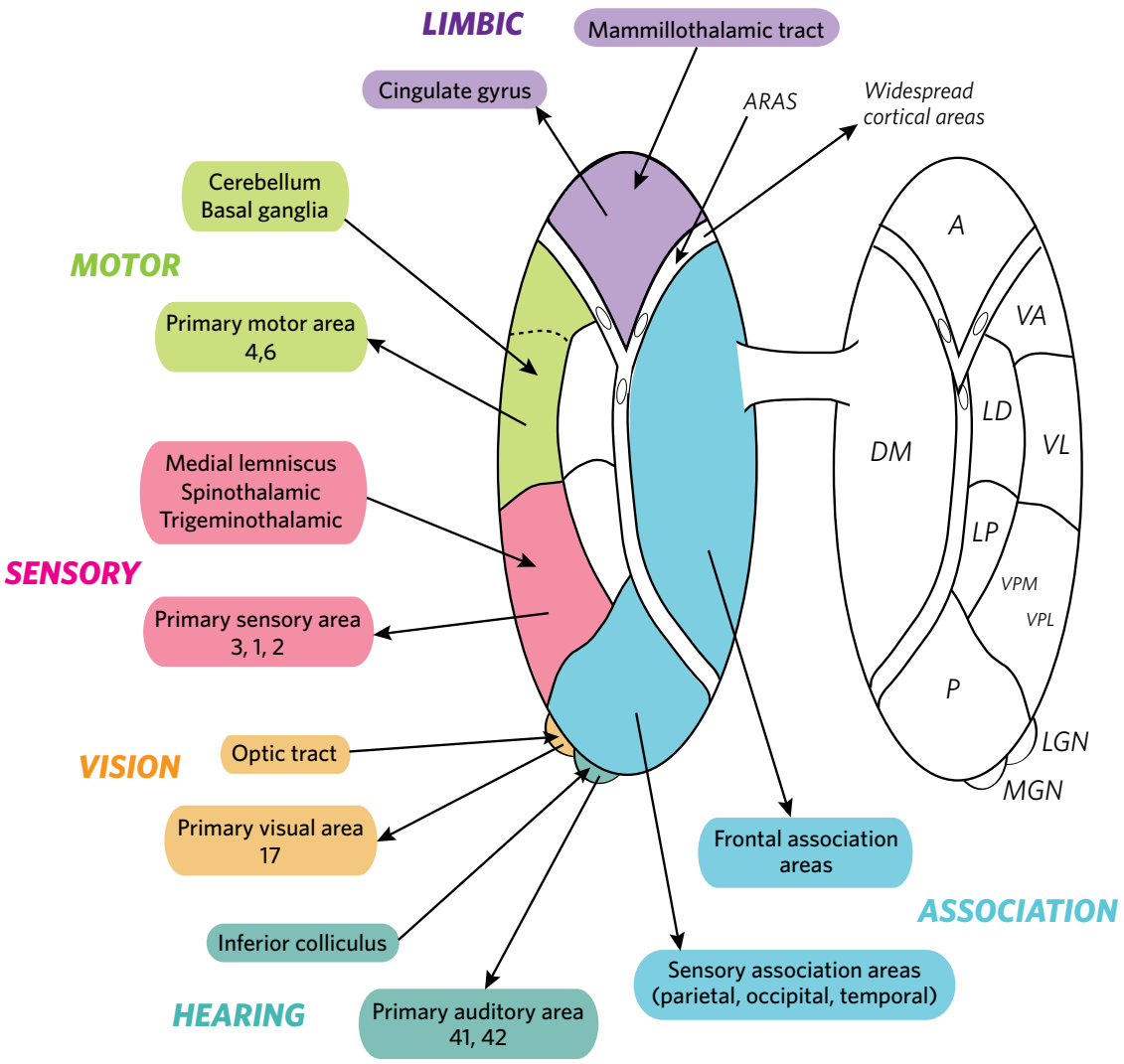

Modified from Neuroanatomy Primer Color to Learn by M.E. McNeill. For educational use only. Copyright © 1997 by Williams & Wilkins. All rights reserved.

Clinical Note

A small lesion in the thalamus can mimic a larger cortical or subcortical (fiber tract) lesion.

February 2, 2026 - Dr. Stiver (mikaela.stiver@ubc.ca)

Identify the following:

- Relationship of the thalamus to:
  - Ventricles
  - Internal capsule
- Lateral Geniculate Nucleus (LGN) - with superior brachium connecting to superior colliculus
- Medial Geniculate Nucleus (MGN) - with inferior brachium connecting to inferior colliculus

Medial Brain

Hide Labels

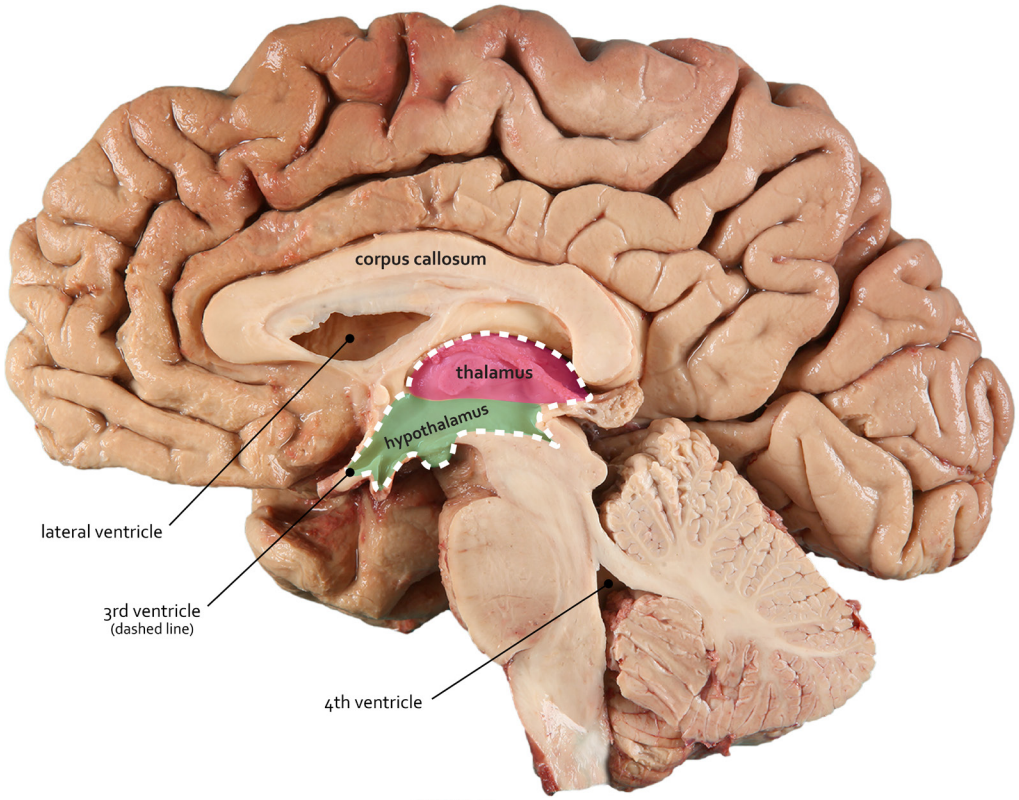

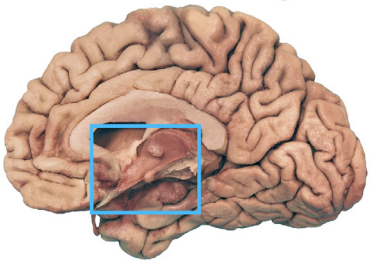

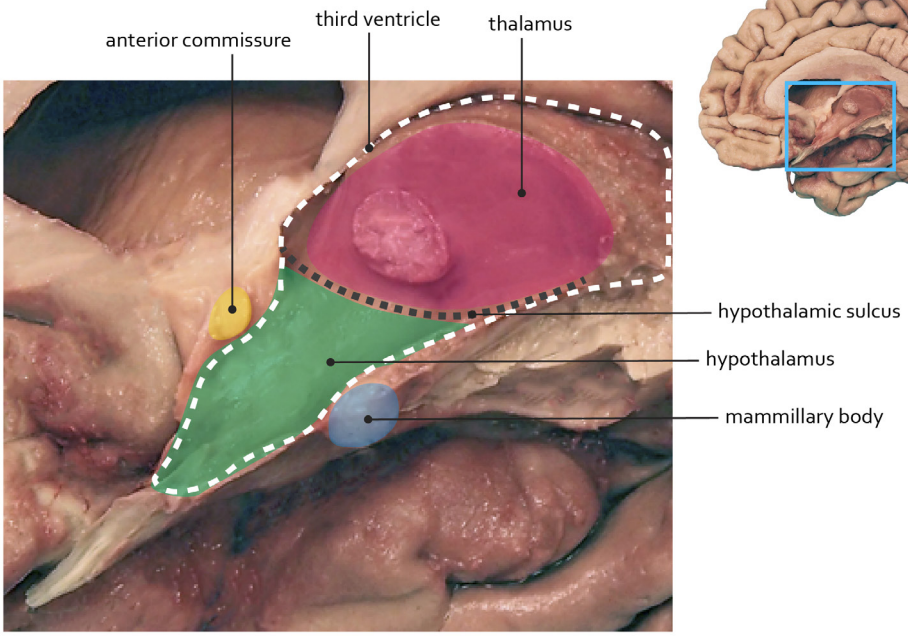

Hide Labels

Visual System

Visual Pathway (Video)

Visual System (Module)

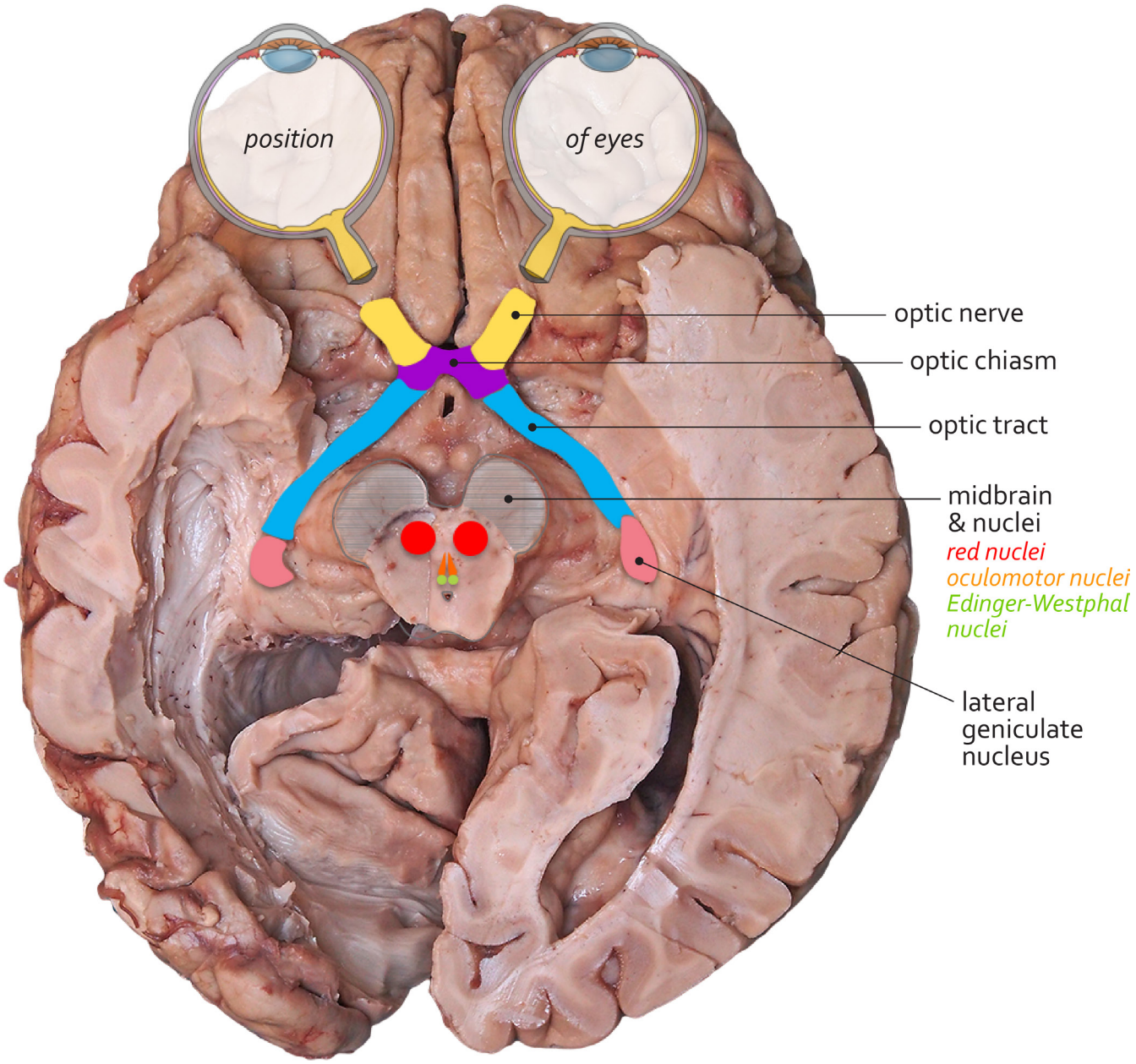

Visual System on Mid-Horizontal Section of Brain
(Inferior View)

Draw in the projection from the visual field to the retina, and from there to the cortex:

Visual Tracts (3D)

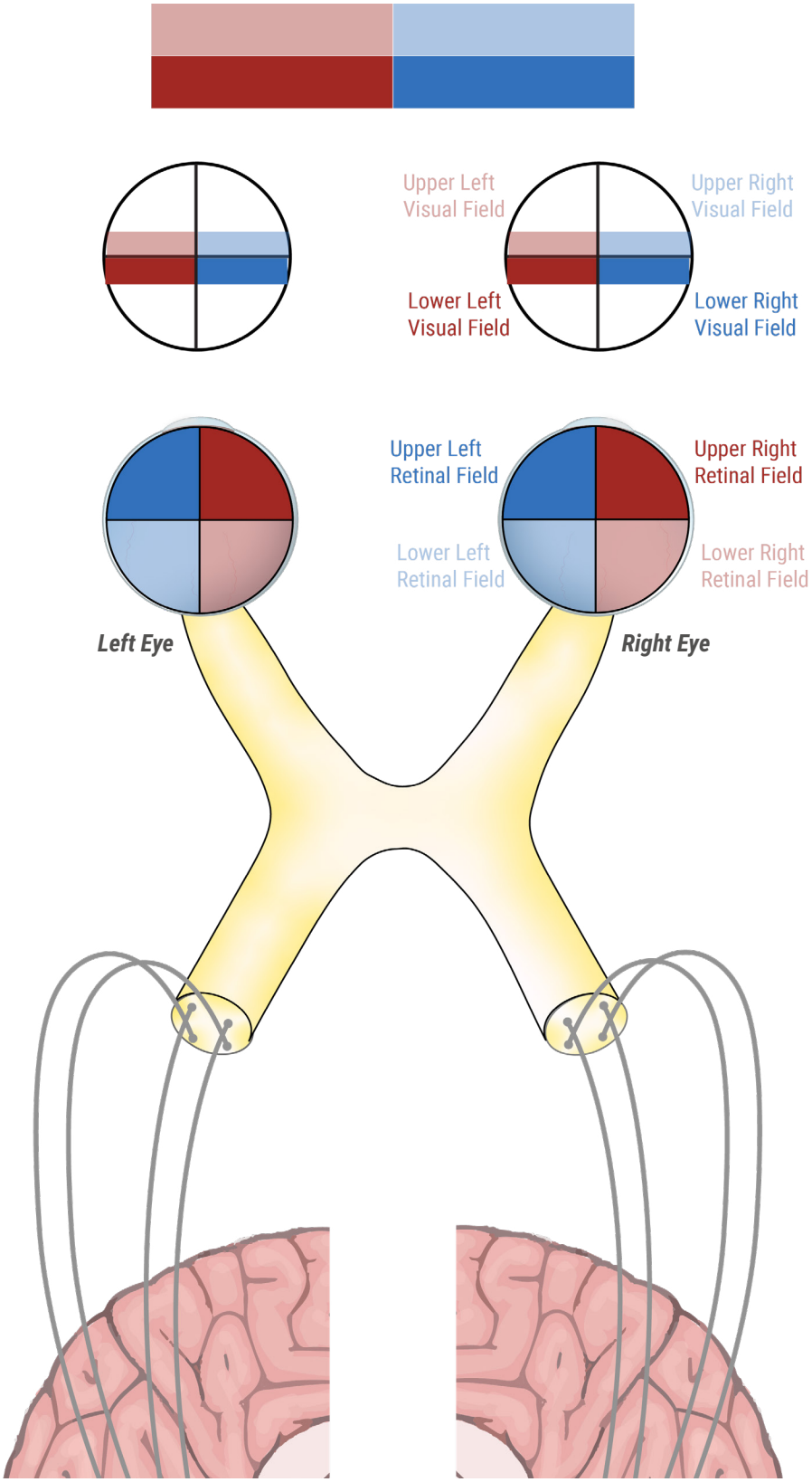

Visual Environment

Visual Field for Each Eye (what you see)

Retina in Each Eye

February 2, 2026 - Dr. Stiver (mikaela.stiver@ubc.ca)

Identify on 3D specimens:

- ◯ optic nerve
- ◯ optic chiasm
- ◯ optic tract
- ◯ lateral geniculate body
- ◯ optic radiations
- ◯ primary visual cortex

Whole Brain 1 (3D)

Whole Brain 2 (3D)

Optic Radiations (3D)

Which visual field deficit would be seen with the lesions indicated below?

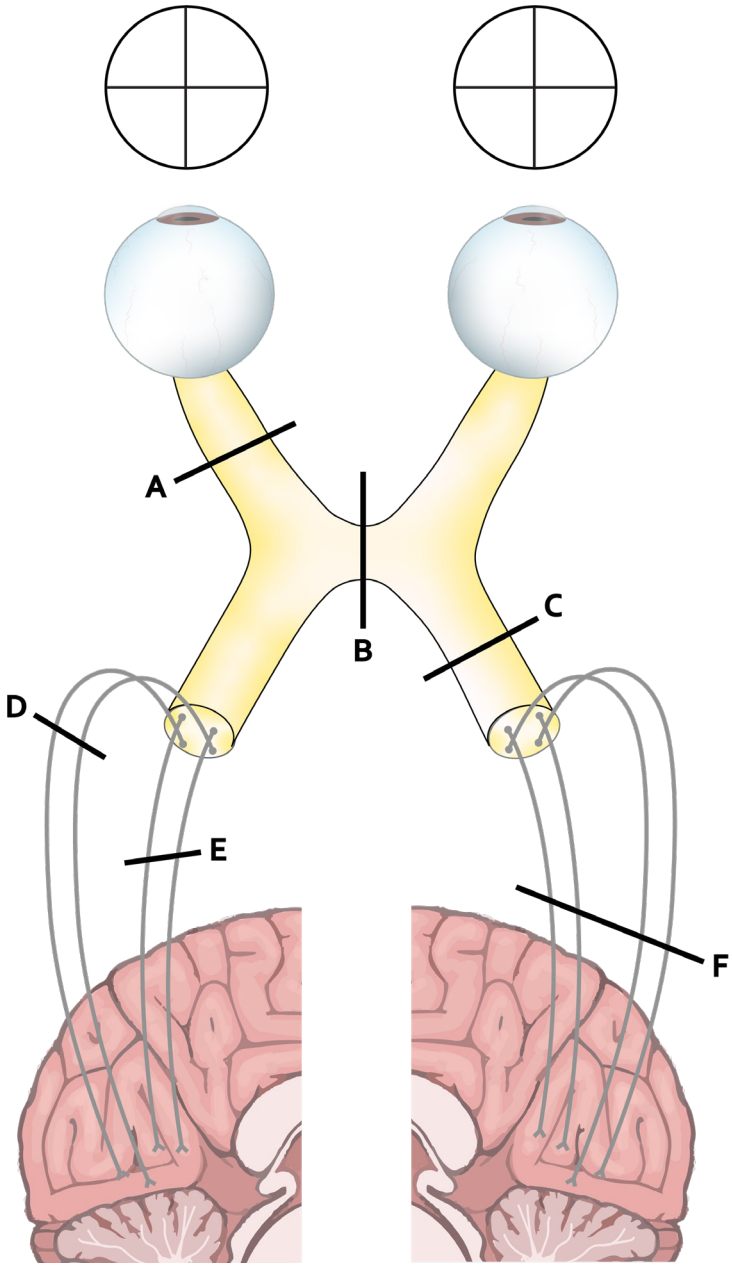

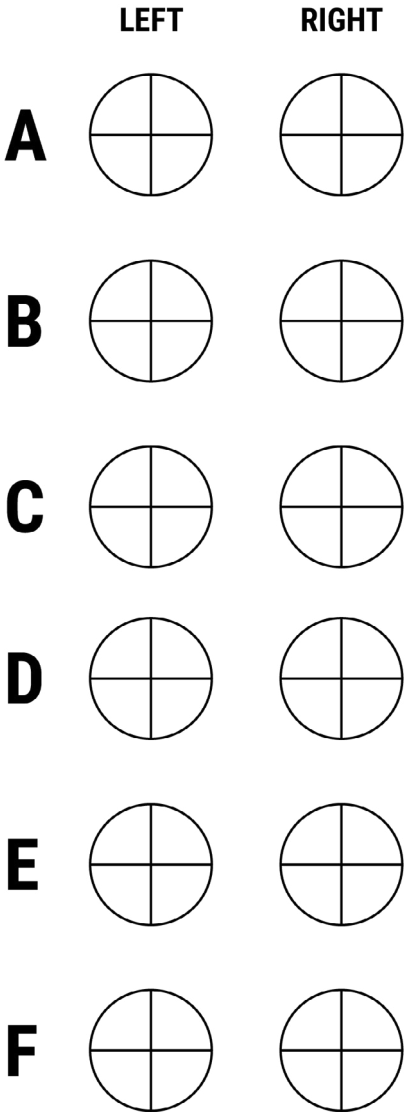

February 2, 2026 - Dr. Stiver (mikaela.stiver@ubc.ca)

Case #2

Noah, a 31 year old right-handed man (he/him) presents with sudden severe neck pain on the right. He reports difficulty seeing on his left side.

Pertinent finding in the neurological exam: left homonymous hemianopsia.

Illustration: Milo Applejohn

What is homonymous hemianopsia?

Where in the visual pathway could the lesion be?

February 2, 2026 - Dr. Stiver (mikaela.stiver@ubc.ca)

Blood Supply

Horizontal Sections (Web)

Coronal Sections (Web)

Whole Brain

- ◯ Cerebral arterial circle and all major branches:
  - ◯ Middle cerebral artery (MCA)
  - ◯ Anterior cerebral artery (ACA)
  - ◯ Posterior cerebral artery (PCA)
  - ◯ Anterior choroidal artery
- ◯ Superior cerebellar artery
- ◯ Anterior inferior cerebellar artery
- ◯ Posterior inferior cerebellar artery
- ◯ Basilar artery
- ◯ Vertebral artery
- ◯ Perfusion areas of the major vessels supplying the cortex (ACA, MCA, PCA)

Coronal and Horizontal Sections

- ◯ Perfusion areas of the major vessels supplying deep structures of the forebrain

Draw in the deep branches of the middle cerebral artery:

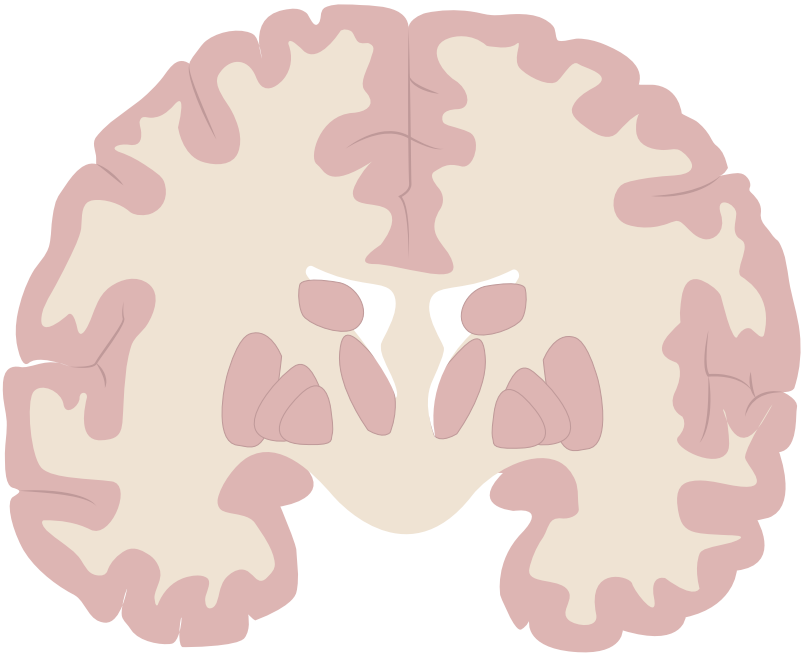

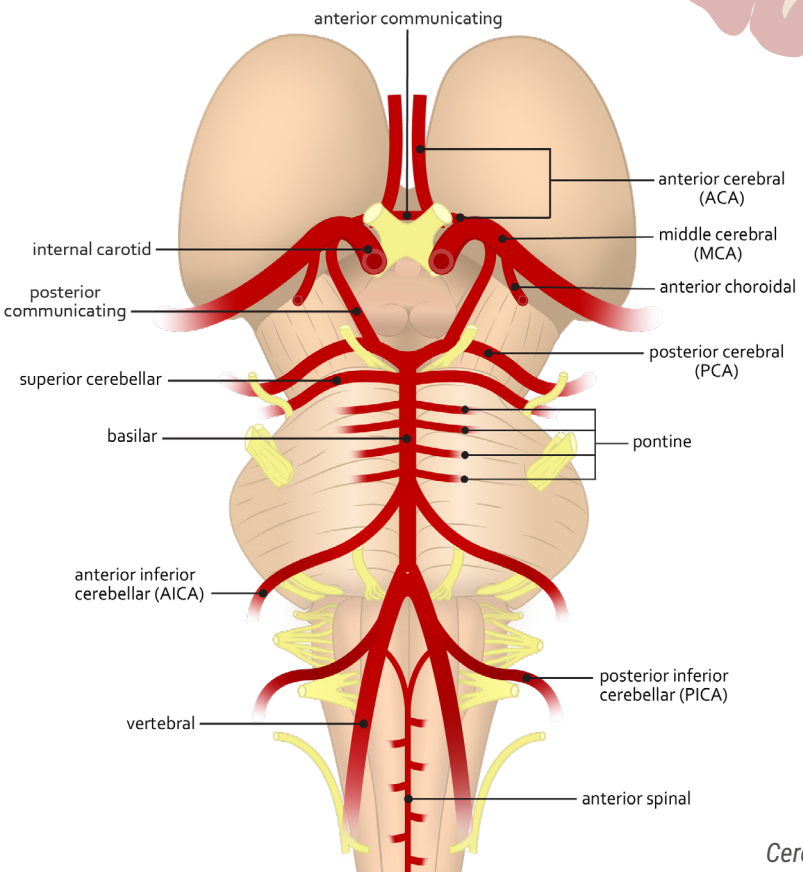

Cerebral Arterial Circle (3D)

Cerebral Arterial Circle on Brainstem

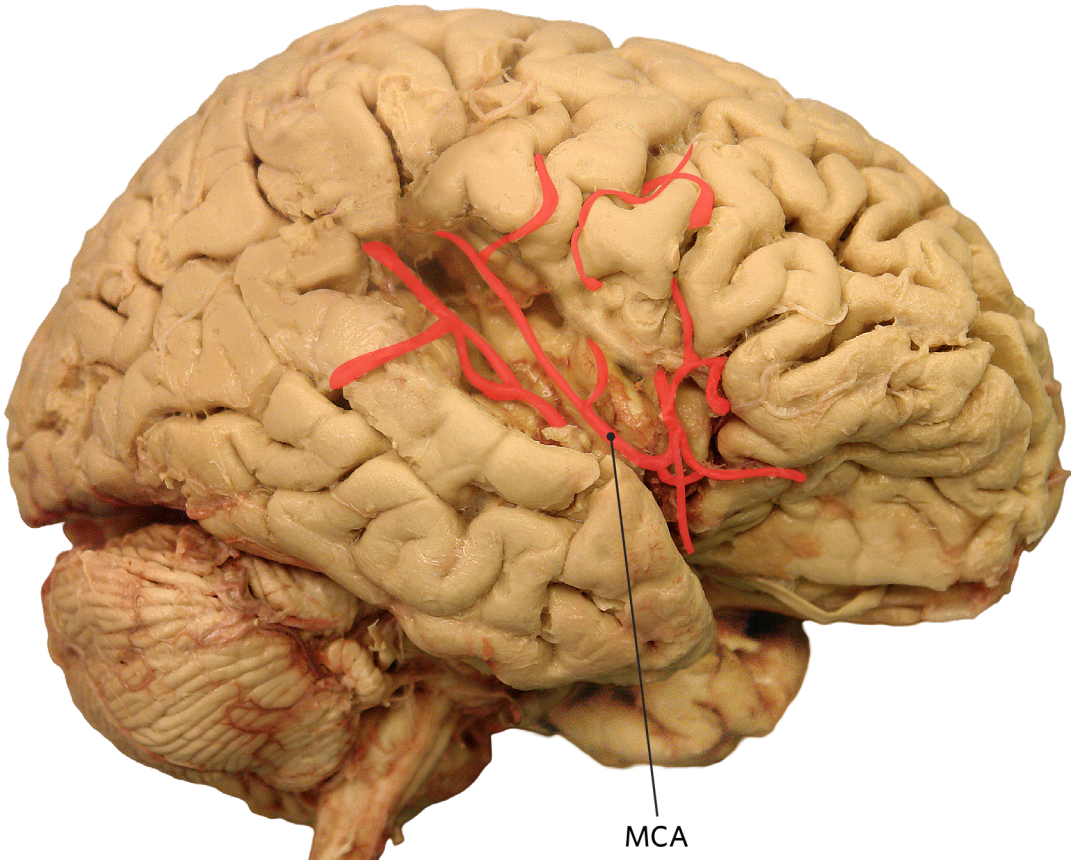

MCA in Lateral Brain

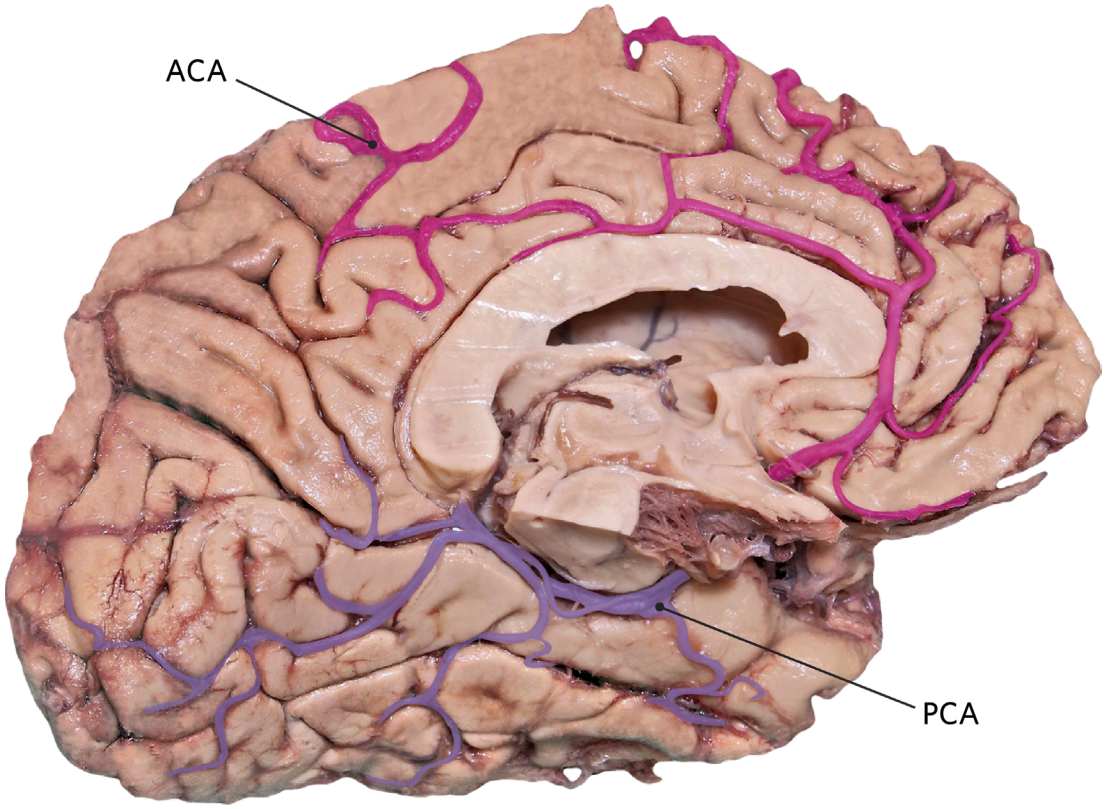

ACA and PCA in Medial Brain

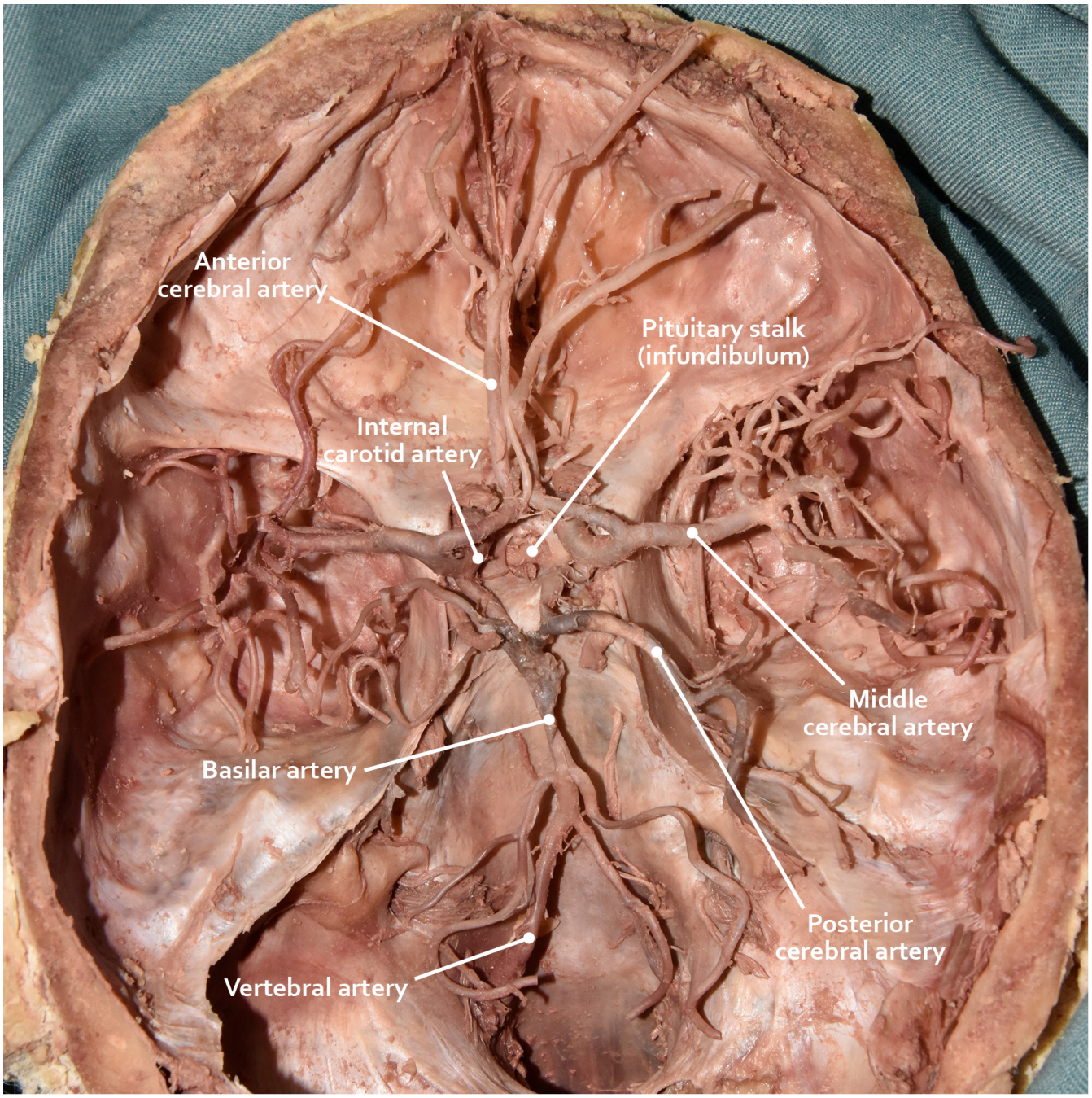

Cerebral Arterial Circle in Cranial Cavity

Hide Labels

The Cortex (CN II)

February 2, 2026 - Dr. Stiver (*mikaela.stiver@ubc.ca*)

Using the stroke model on the neuroanatomy website, sketch in the perfusion areas of the anterior cerebral, middle cerebral (including deep branches), posterior cerebral and anterior choroidal arteries.

Interactive atlas with cross-sections:

Horizontal Sections (Web)

Coronal Sections (Web)

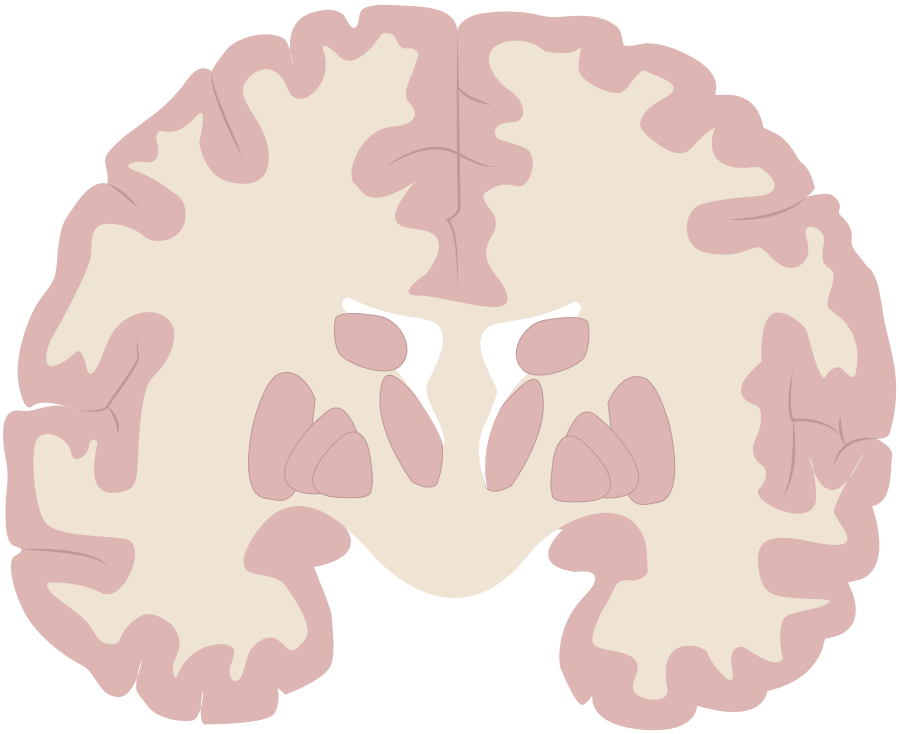

February 2, 2026 - Dr. Stiver (mikaela.stiver@ubc.ca)

Which cortical area would the following descriptions of lesions be most likely associated with?

1. Deficits in the ability to recognize objects in the opposite visual field (visual agnosia).

2. Deficits in the ability to combine touch, pressure and proprioceptive information to interpret the significance of sensory information (tactile agnosia) and the inability to recognise an object placed in the hand (tactile agnosia).

3. Personality changes, deficits in executive function.

4. Decreased perception of sound, primarily in the contralateral ear.

5. Deficits in learned, skilled motor activities (apraxia).

6. Expressive or production aphasia - sparse, halting language, difficulty with syntax and grammar, word/phrase repetition and mangled word structure.

RESOURCES

Websites:

Neuroanatomy | Entrada

Recommended Textbooks:

Lippincott Illustrated Reviews: Neuroscience
By: Claudia Krebs, Joanne Weinberg, Elizabeth J. Akesson, Esma Dilli
Lippincott Williams & Wilkins
ISBN 978-1-4963-6789-1

Neuroanatomy Through Clinical Cases
By: Hal Blumenfeld
Sinauer
ISBN 978-0-8789-3613-7

Neuroanatomy in Clinical Context: An Atlas of Structures, Sections, Systems, and Syndromes
By: Duane E. Haines
Wolters kluwer Health
ISBN 978-1-4511-8625-3

ACKNOWLEDGEMENTS

Artwork & Design:

The HIVE, UBC Faculty of Arts

Instructional Design: Monika Fejtek
Medical Illustration Lead: Paige Blumer
Academic Lead: Claudia Krebs

Prosector: Lien Vo

Content Review: Esma Dilli